Ultrasound in COVID-times

The dyspnoic patient COVID?

Prof. Dr. Frank H. Bosch
Internist Rijnstate hospital and Radboudumc

Radboudumc

I have nothing to disclose

Radboudumc

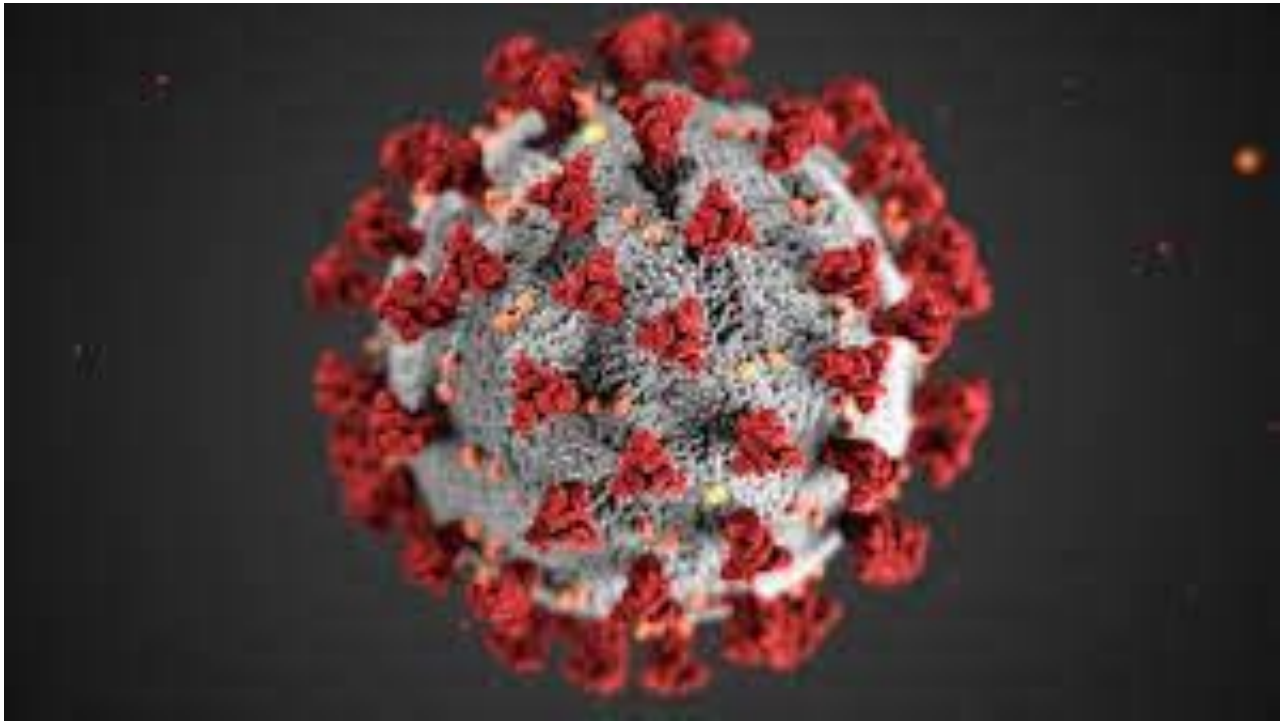

Typical x-ray in COVID-19

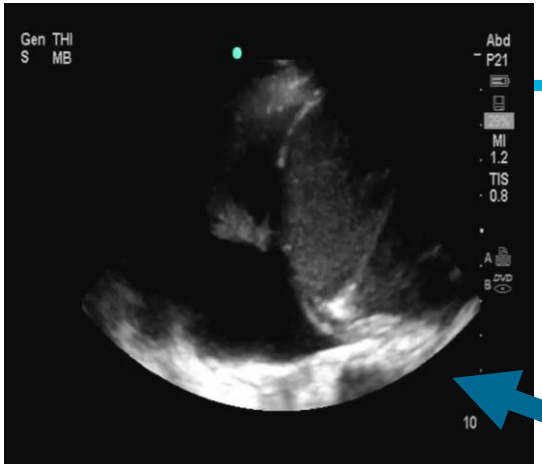
Gen THI
S MB
Abd
P21
MI
1.2
TIS
0.8
10

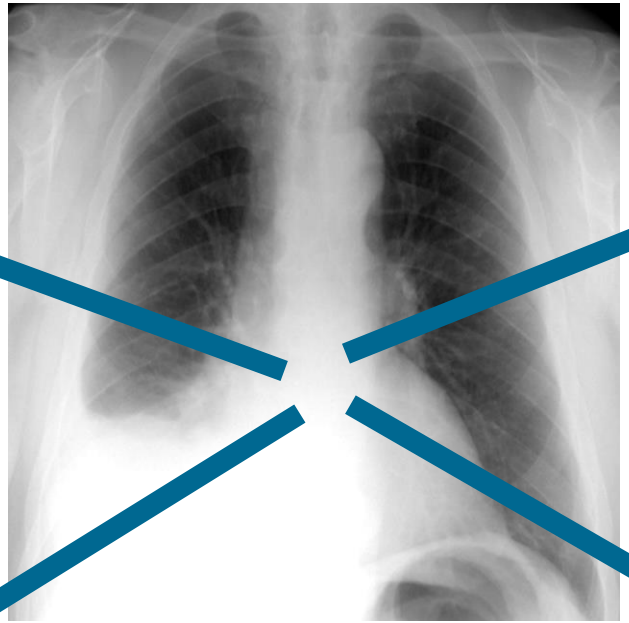

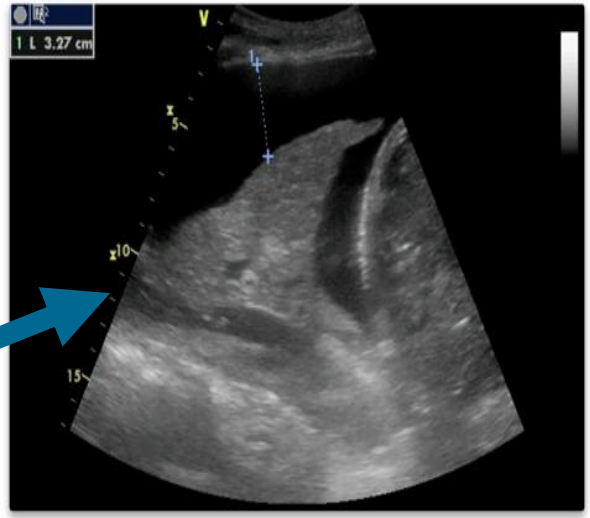
1 L 3.27 cm
V
5
10
15

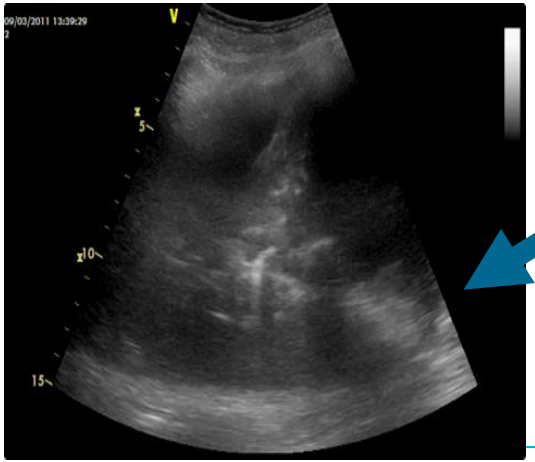
09/03/2011 13:39:29
V
5
10
15

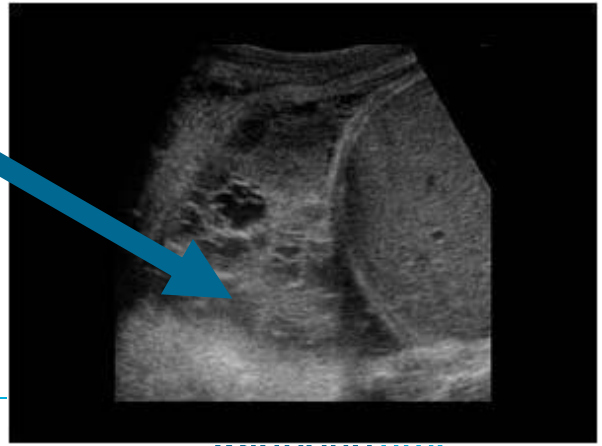

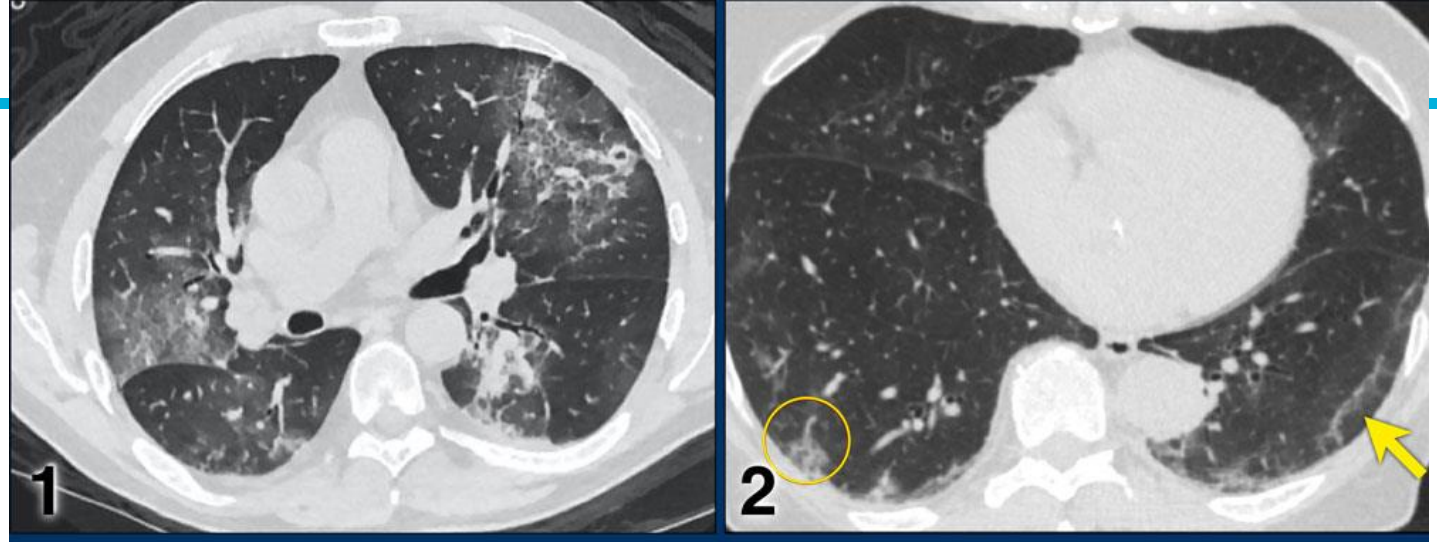

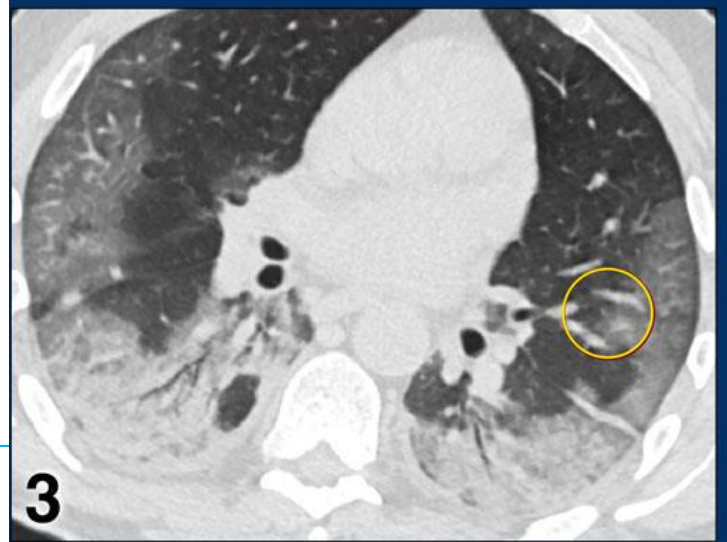

27 April 2020
Dutch Radiological Society

umc

CO-RADS*

Level of suspicion COVID-19 infection

		CT findings
CO-RADS 1	No	normal or non-infectious abnormalities
CO-RADS 2	Low	abnormalities consistent with infections other than COVID-19
CO-RADS 3	Indeterminate	unclear whether COVID-19 is present
CO-RADS 4	High	abnormalities suspicious for COVID-19
CO-RADS 5	Very high	typical COVID-19
CO-RADS 6	PCR +	

Linear
Curvilinear
Phased Array
12L
3Sc

Linear probe

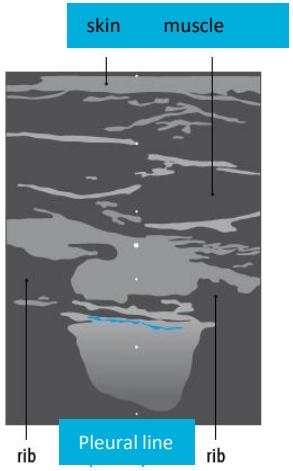

Lungsliding; Convex probe

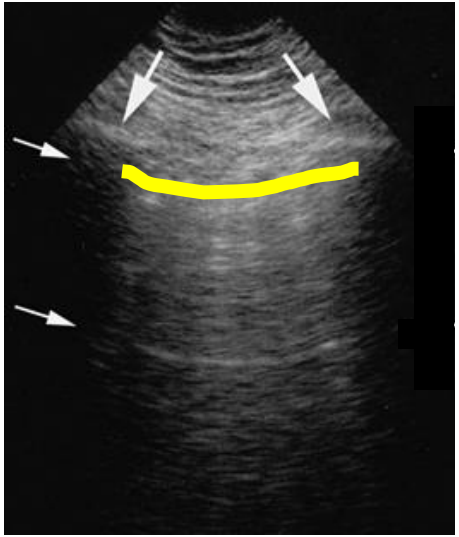

PHILIPS
BOSCH
[redacted]
Rijnstate IC
MI 0,8
TIS 0,1
1-9-2013
17:51:04
JPEG CR 37:1
Arterial
C8-5
68 Hz
2,5cm
2D
Gen
Gn 50
C 41
3/3/2
P
2
2,5cm
G
P
R
5,0 8,0

umc


Aan/uit
Probe selectie
2D
Gain
Depth
Focus
Freeze
Afstand meten

umc

Scan
Thea
OS
All Studies
Smith, Dana
Aaron Dan
Garcia, Emily
Aaron Dan
Jones, Sarah

Quick ID
END EXAM
Fast Flow
MMode
Depth
Gain
Slow Flow
Save Loop
PHILIPS
Lumify

HEKA
ALCOHOL PREPS
70% ISOPROPYL ALCOHOL
6,5 X 3 CM
HEKA
ALCOHOL PREPS
70% ISOPROPYL ALCOHOL
6,5 X 3 CM
VAN HEEK MEDICAL
HEKA
ALCOHOL PRE
ALCOHOL
70% ISOPROPYL ALCOH
6,5 X 3 CM
REF HD
100 X 1

UVsmart
EMERGENCY UNIT

Left

COVID-19 image comparable to viral pneumonia

- Thickened irregular pleura
- B-lines with inhomogeneous distribution
- Confluant B-lines (Waterfall fenomeen)
- Subpleural infiltrates
- No pleural fluid

Characteristic COVID-19: B-lines & waterfall

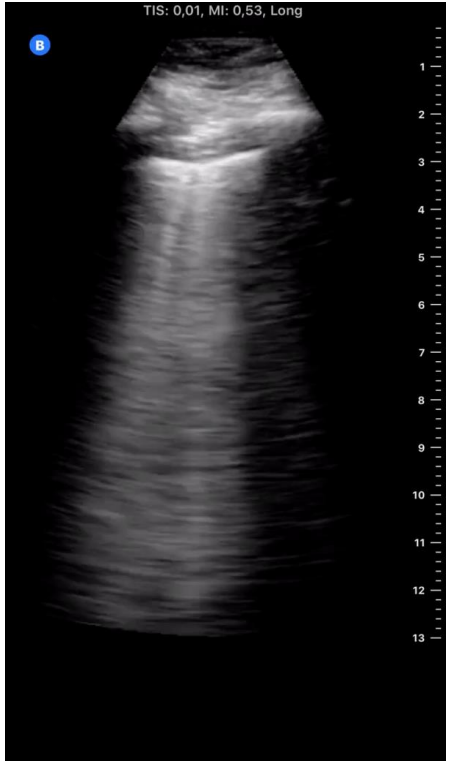

Characteristic COVID-19 image: B-lines & subpleural consolidation

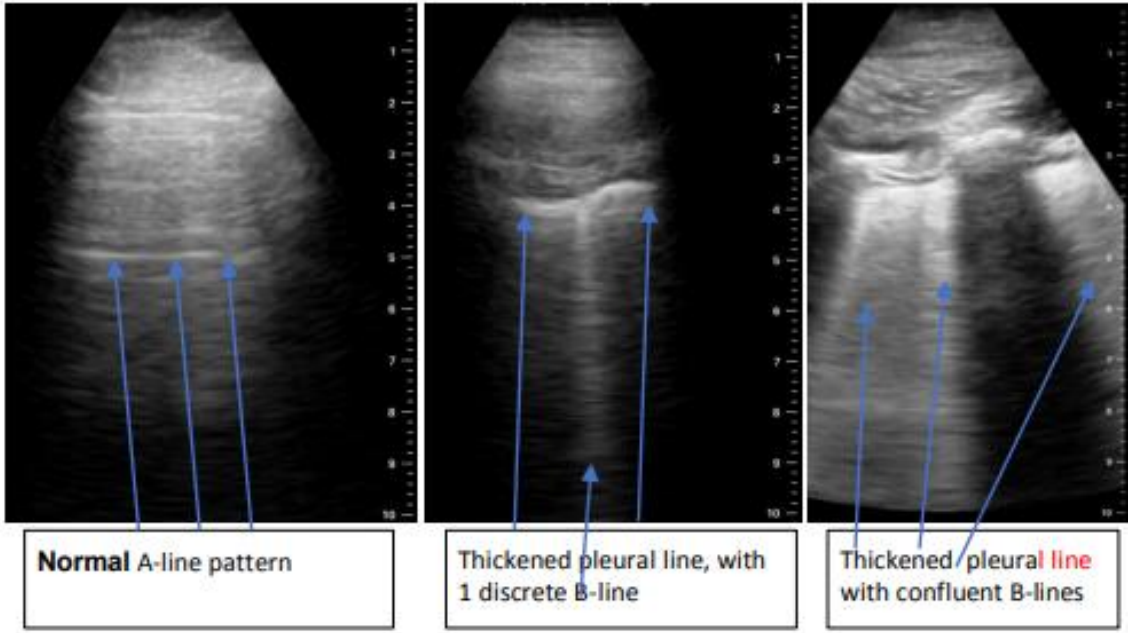
Normal A-line pattern
Thickened pleural line, with 1 discrete B-line
Thickened pleural line with confluent B-lines

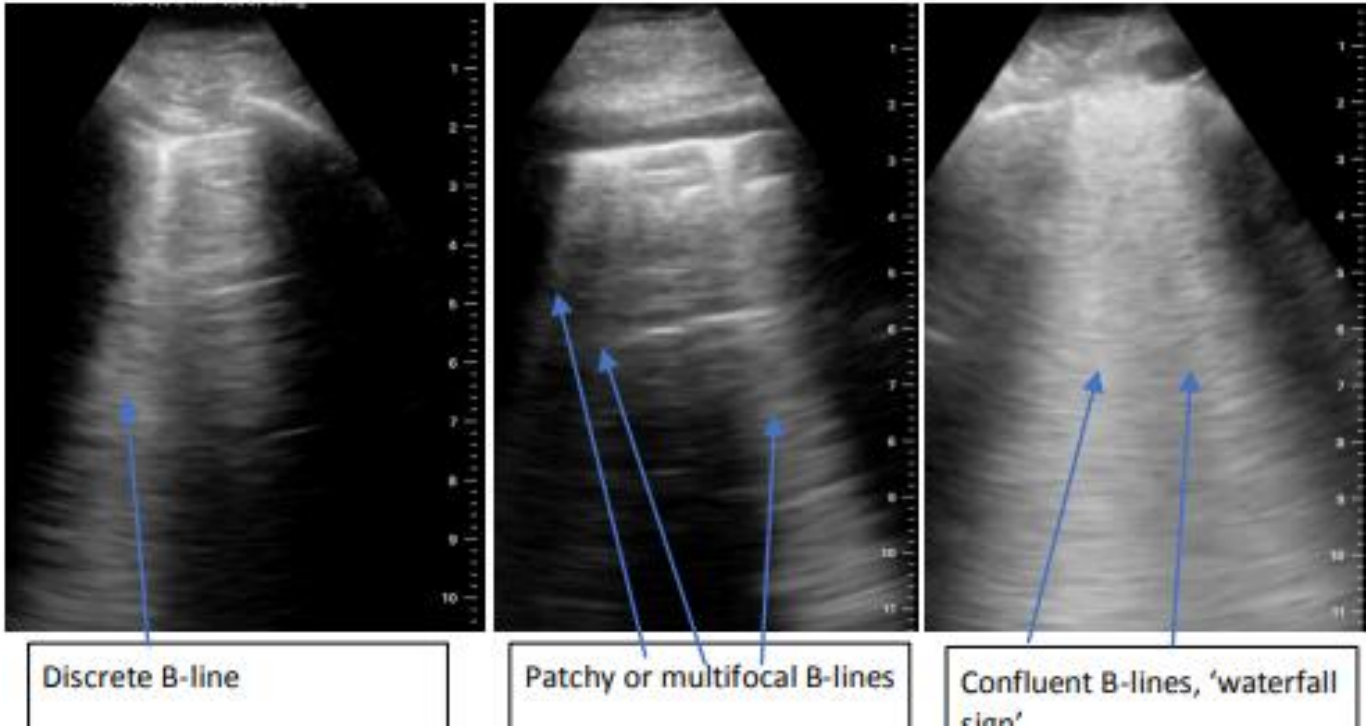
Discrete B-line
Patchy or multifocal B-lines
Confluent B-lines, 'waterfall sign'

Small subpleural consolidation or 'skip' lesion

Large subpleural consolidation

2 Protocols



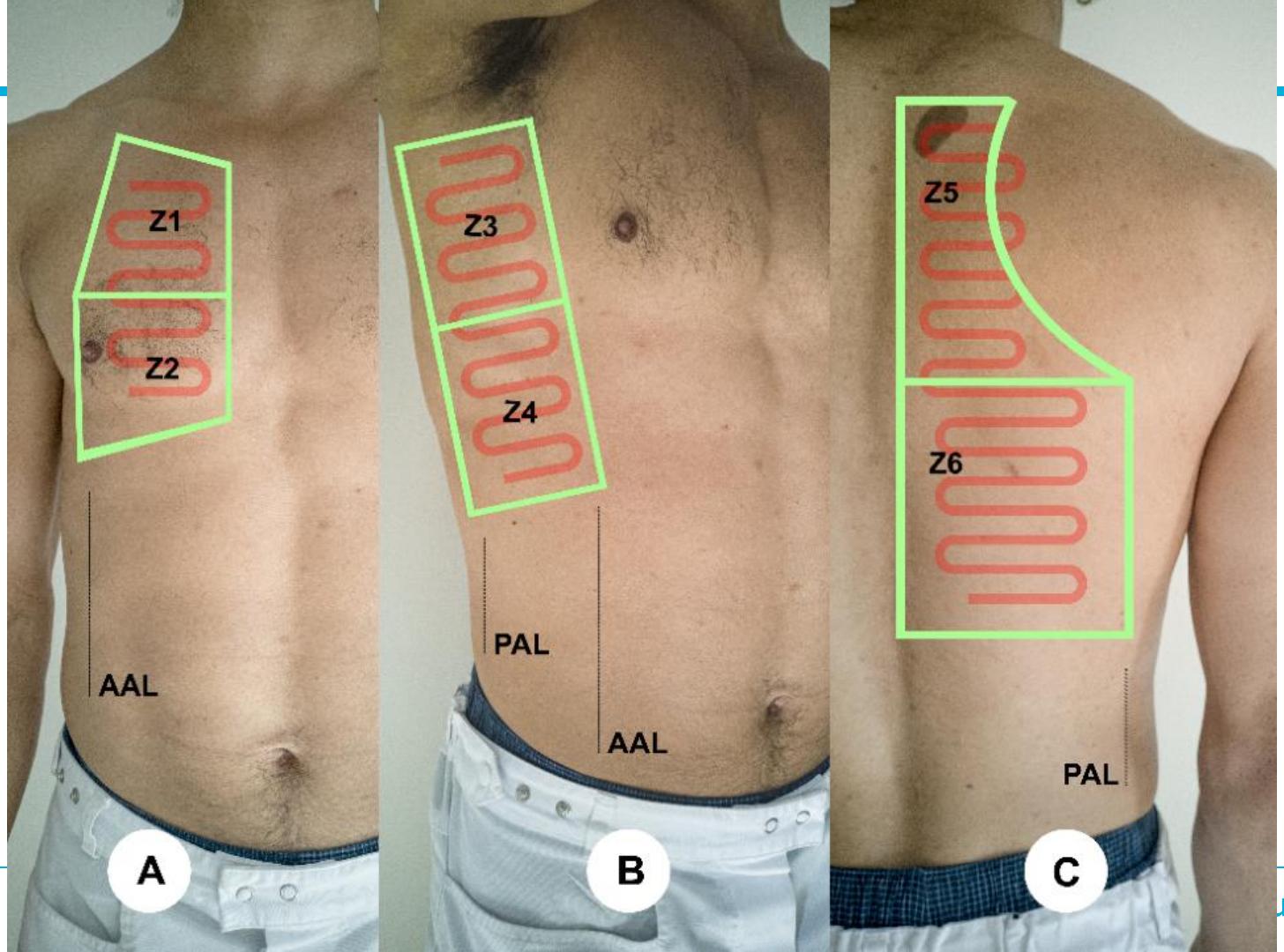

umc

No. points	Aeration	Description	Appearance
0	Normal	A-line pattern with maximum of 2 B-lines per sector	
1	Moderate loss	Multiple B-lines regularly spaced or coalescent but within a limited portion of sector	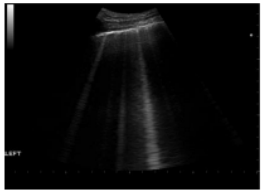
2	Severe loss	Coalescent B-lines throughout a sector	
3	Total loss	Lung consolidation	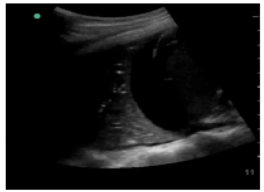

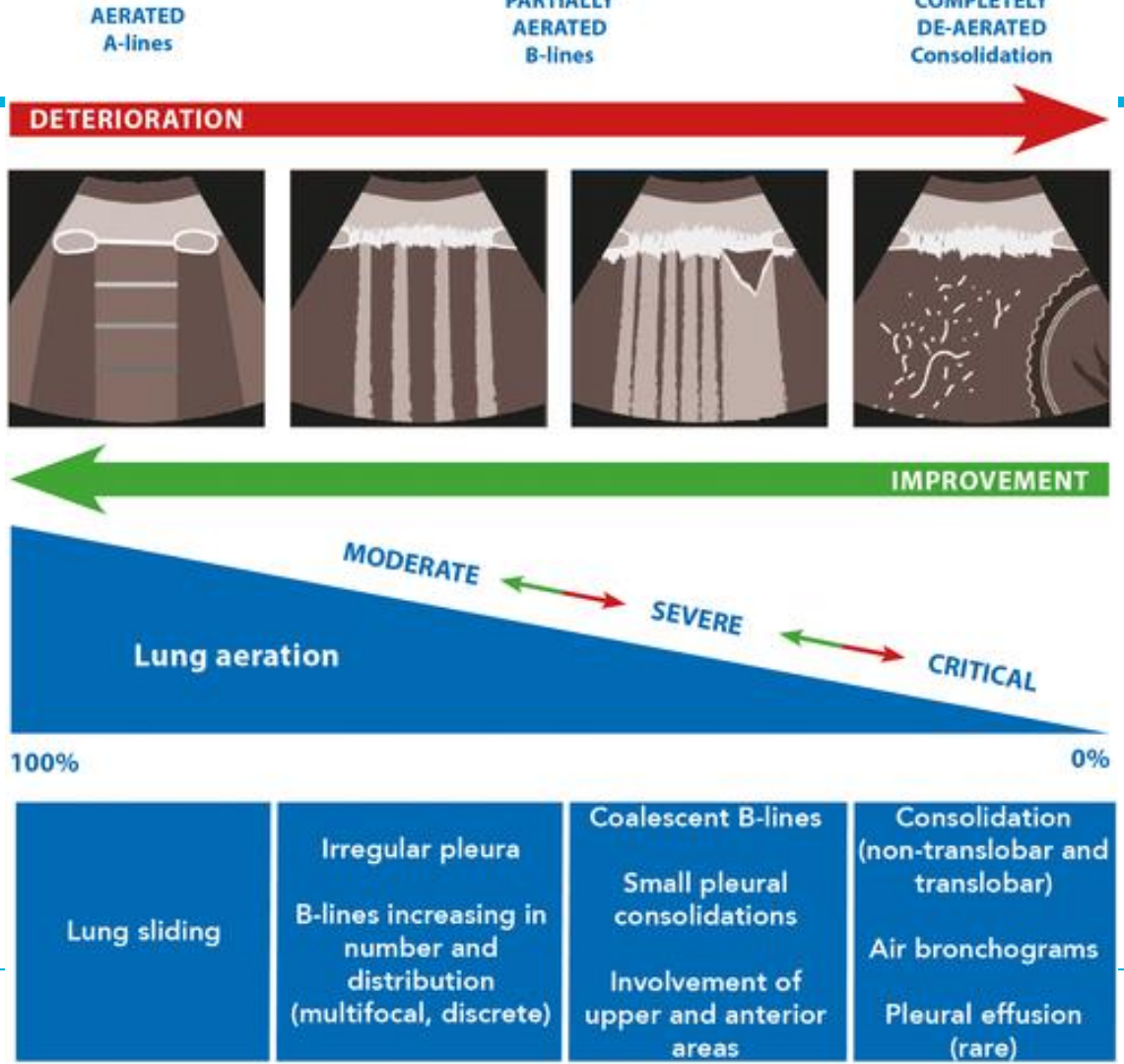

Smith et al.
Anesthesia 2020

Lung Ultrasound & CT criteria

- LUS was deemed positive

- Three or more B-lines and/or consolidation in two or more zones unilaterally
- Three or more B-line and/or consolidation in one or more zones bilaterally.

- LUS was deemed negative

- COVID-19 features were not found or just in one zone unilaterally

- CT was deemed positive

- A CO-RADS score of 5 or 6 is regarded as positive

- CT was deemed negative

- A CO-RADS score of 1 or 2 is regarded as negative

- A score of 3 is equivocal; for the purpose of this study equivocal CTs were considered negative.

ERJ open research
THE BEST IN OPEN ACCESS BASIC, TRANSLATIONAL & CLINICAL RESPIRATORY RESEARCH

ERJ Open Research

ERJ Open Res. 2020.

PMCID: PMC7569754

Published online 2020 Dec 21. doi: 10.1183/23120541.00539-2020

PMID: 33442553

Diagnosing COVID-19 pneumonia in a pandemic setting: Lung Ultrasound *versus* CT (LUVCT) – a multicentre, prospective, observational study

Arthur W.E. Lieveld,[1,6] Bram Kok,[2,6] Frederik H. Schuit,[1,6] Kaoutar Azijli,[3] Jarom Heijmans,[4] Arjan van Laarhoven,[2] Natascha L. Assman,[2] Ruud S. Kootte,[4] Tycho J. Olgers,[5] Prabath W.B. Nanayakkara,[1] and Frank H. Bosch[2]

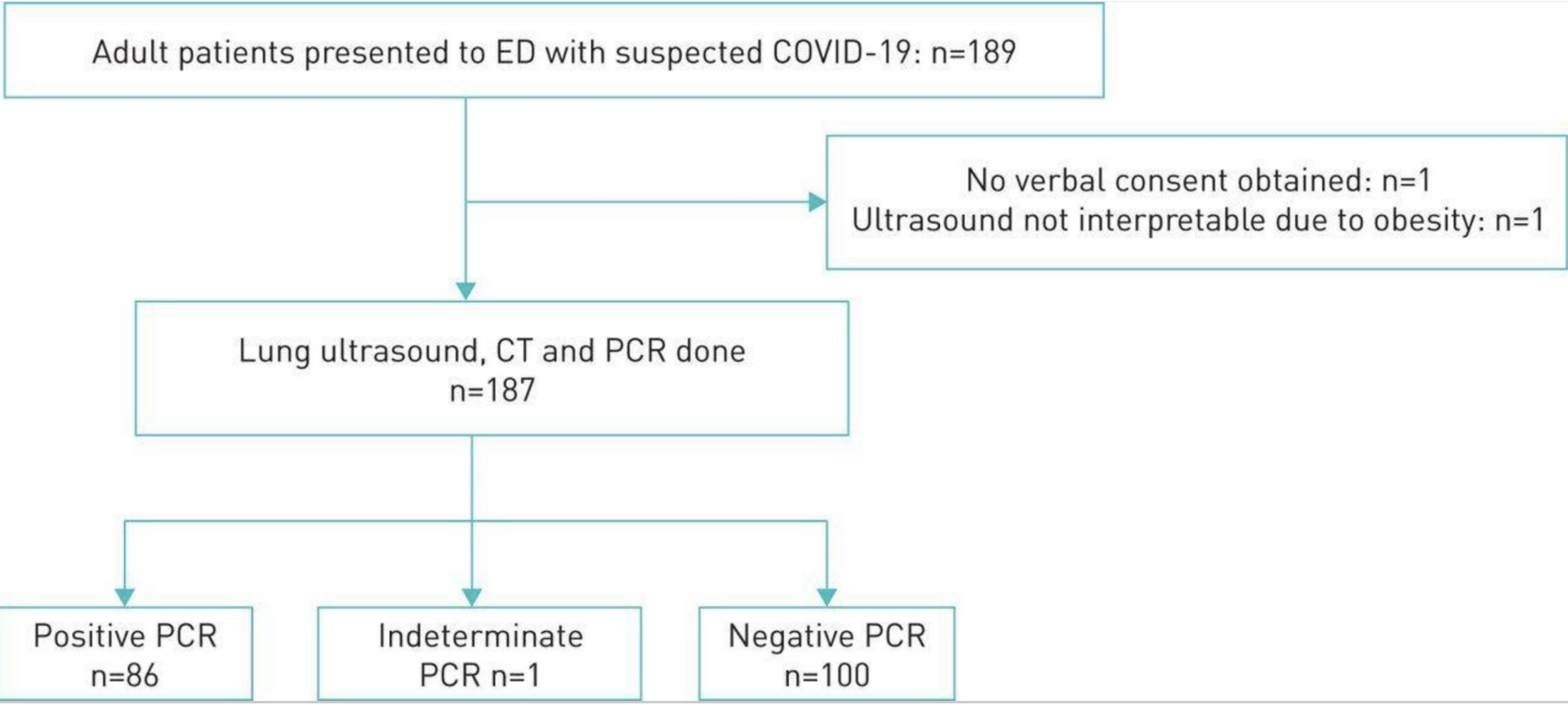
Adult patients presented to ED with suspected COVID-19: n=189
No verbal consent obtained: n=1
Ultrasound not interpretable due to obesity: n=1
Lung ultrasound, CT and PCR done
n=187
Positive PCR
n=86
Indeterminate
PCR n=1
Negative PCR
n=100

TABLE 2

Diagnostic results

	PCR positive	PCR negative	Final diagnosis
Lung ultrasound: positive	79	29	91
Lung ultrasound: negative	7	71	10
CT: positive	76	18	
CT: negative	10	82	

Data are presented as n. CT: computed tomography.

TABLE 3

Diagnostic accuracy for COVID-19

	Lung ultrasound *versus* PCR	CT *versus* PCR	Lung ultrasound *versus* COVID-19 diagnosis[#]
Sensitivity % (95% CI)	91.9 (84.0–96.7)	88.4 (79.7–94.3)	90.1 (82.5–95.2)
Specificity % (95% CI)	71.0 (61.1–79.6)	82.0 (73.1–89.0)	80.0 (69.9–87.9)
Positive likelihood ratio	3.2 (2.3–4.3)	4.9 (3.2–7.5)	4.5 (2.9–6.9)
Negative likelihood ratio	0.1 (0.06–0.24)	0.14 (0.08–0.26)	0.12 (0.07–0.2)
PPV % (95% CI)	73.2 (66.6–78.8)	80.9 (73.4–86.6)	84.2 (77.7–89.2)
NPV % (95% CI)	91.0 (83.1–95.4)	89.1 (82.0–93.7)	90.8 (81.7–95.6)
Accuracy % (95% CI)	80.7 (74.2–86.1)	85.0 (79.0–89.8)	82.8 (76.6–87.9)

CT: computed tomography; COVID-19: coronavirus disease 2019; PPV: positive predictive value; NPV: negative predictive value; CI: confidence interval. [#]: According to multidisciplinary team, COVID-19 is highly likely.

LUS and CT have comparable diagnostic accuracy for COVID-19 pneumonia. LUS can safely exclude clinically relevant COVID-19 pneumonia and may aid COVID-19 diagnosis in high prevalence situations.

Table 3

Correlation: LUS score according to chest CT scan severity

Chest CT scan severity	Patients	LUS score mean ± SD	95% CI for Mean		LUS score min	LUS score max	*P* value
			Lower bound	Upper bound			
Minimal damage	18	8 ± 7	4	11	0	22	< 0.0001
Moderate damage	43	14 ± 8	11	16	0	30	
Severe damage	39	20 ± 8	18	23	5	34	

CT computed tomography; *LUS* lung ultra

Comparative study of lung ultrasound and chest computed tomography scan in the assessment of severity of confirmed COVID-19 pneumonia

Laurent Zieleskiewicz,[#1,2] Thibaut Markarian,[#3] Alexandre Lopez,[1] Chloé Taguet,[3] Neyla Mohammedi,[1] Mohamed Boucekine,[4] Karine Baumstarck,[4] Guillaume Besch,[5] Gautier Mathon,[6] Gary Duclos,[1] Lionel Bouvet,[7,8,9] Pierre Michelet,[3] Bernard Allaouchiche,[6,8,9] Kathia Chaumoître,[10] Mathieu Di Bisceglie,[10] Marc Leone,[1] and on behalf of the AZUREA Network

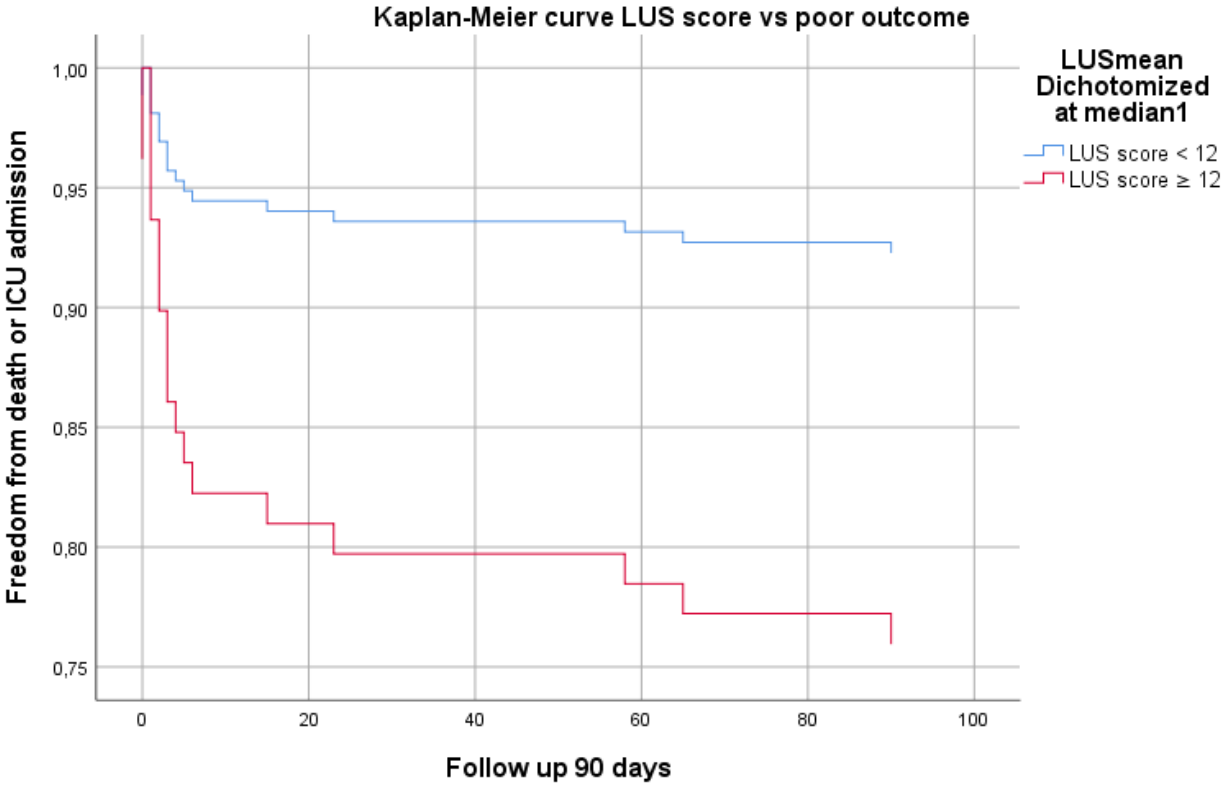
Kaplan-Meier curve LUS score vs poor outcome
Freedom from death or ICU admission
1,00
0,95
0,90
0,85
0,80
0,75
0
20
40
60
80
100
Follow up 90 days
LUSmean Dichotomized at median1
LUS score < 12
LUS score ≥ 12

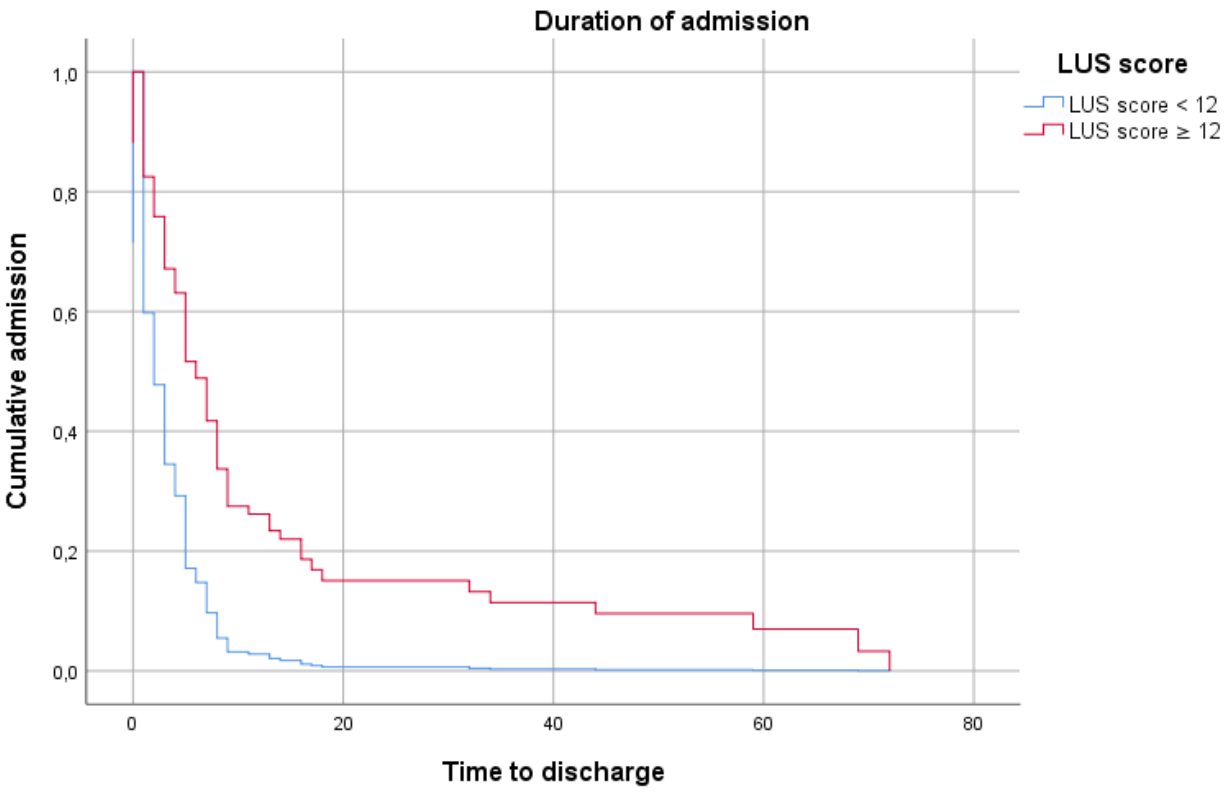
Duration of admission
LUS score
LUS score < 12
LUS score ≥ 12
Cumulative admission
1,0
0,8
0,6
0,4
0,2
0,0
0
20
40
60
80
Time to discharge

LUS score vs c

- Low LUS score

- High LUS score
- Intermediate LUS score

Lung ultrasound score predicts outcomes in COVID-19 patients admitted to the emergency department

Julio Cesar Garcia de Alencar[1*], Julio Flavio Meirelles Marchini[1], Lucas Oliveira Marino[1], Sabrina Correa da Costa Ribeiro[1], Cauê Gasparotto Bueno[1], Victor Paro da Cunha[1], Felippe Lazar Neto[1], Rodrigo Antonio Brandão Neto[1], Heraldo Possolo Souza[1] and the COVID U. S. P. Registry Team[2]

Table 2 LUS and outcomes in patients with COVID-19

	Patients	LUS (mean ± SD)
Primary outcome		
Deceased	61/170 (36%)	21.6 ± 4.9
Discharged alive	109/170 (64%)	16.7 ± 4.9
Secondary outcomes		
Intubated	52/133 (39%)	21.3 ± 4.9
Not intubated	81/133 (61%)	15.2 ± 7.1
Admitted to ICU	74/133 (56%)	20.0 ± 5.9

Cochrane Library

Cochrane Database of Systematic Reviews

Thoracic imaging tests for the diagnosis of COVID-19 (Review)

- Ultrasound is sensitive but not specific for the diagnosis of COVID-19. Thus, chest CT and ultrasound may have more utility for excluding COVID-19 than for differentiating SARS-CoV-2 infection from other causes of respiratory illness.

- **C**omparing **L**ung **U**ltrasound: **E**xtensive vs **S**hort in COVID-19
- **(CLUES)**
-
- A multi-center, prospective, observational study

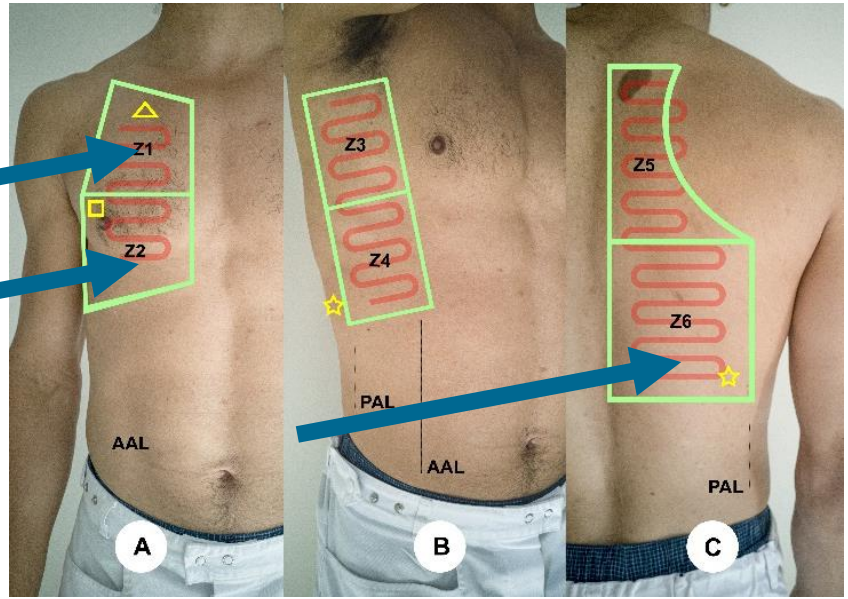

LSS
S
MR
STUDIO BOOT / WERKPLAATS VOOR BEELD & TYPOGRAFIE
van Tuldenstraat 2 5211TG 's-Hertogenbosch

12

vs

6

In a COVID-19 pandemic setting

- Lung Ultrasound is comparable to CT-scanning
- Lung Ultrasound can help in triage
- Lung Ultrasound should be taught as an extension of the physical examination
- Lung Ultrasound is not only useful at the Emergency Department but may also be very useful in the general practice, or in nursing homes
- 6 zones can be used for screening
- Handheld POCUS is here to stay

Questions for the future

How to train future physicians?

- huge workforce of instructors
- bachelor phase of medical study?

Artificial Intelligence for interpretation of Ultrasound Images?

umc

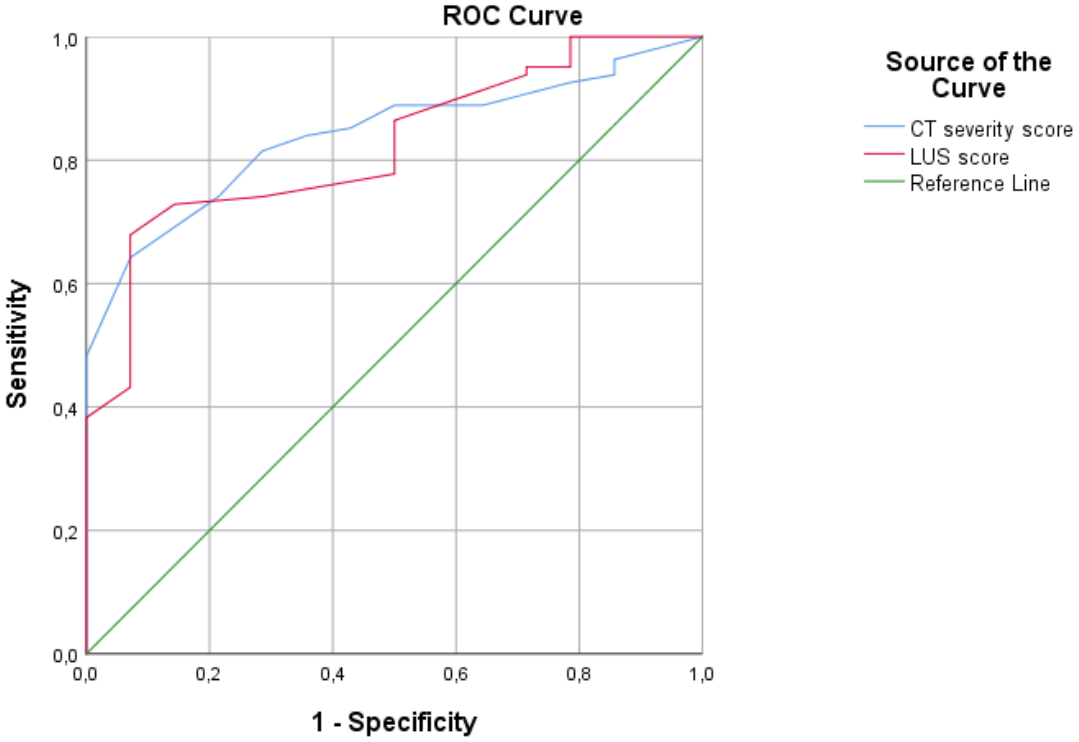

Diagonal segments are produced by ties.